



HAL
open science

How to assess eye movements clinically

Caroline Froment Tilikete

► **To cite this version:**

Caroline Froment Tilikete. How to assess eye movements clinically. *Neurological Sciences*, 2022, 43 (5), pp.2969-2981. 10.1007/s10072-022-05981-5 . ujm-04320558

HAL Id: ujm-04320558

<https://ujm.hal.science/ujm-04320558>

Submitted on 4 Dec 2023

HAL is a multi-disciplinary open access archive for the deposit and dissemination of scientific research documents, whether they are published or not. The documents may come from teaching and research institutions in France or abroad, or from public or private research centers.

L'archive ouverte pluridisciplinaire **HAL**, est destinée au dépôt et à la diffusion de documents scientifiques de niveau recherche, publiés ou non, émanant des établissements d'enseignement et de recherche français ou étrangers, des laboratoires publics ou privés.

Neurological Sciences

HOW TO ASSESS EYE MOVEMENTS CLINICALLY

--Manuscript Draft--

Manuscript Number:	NEUS-D-21-01517R1
Full Title:	HOW TO ASSESS EYE MOVEMENTS CLINICALLY
Article Type:	Review Article
Keywords:	diplopia; ocular motor palsy; gaze palsy; nystagmus; oscillopsia; saccadic intrusions
Corresponding Author:	Caroline Froment Tilikete Hospices Civils de Lyon Bron, FRANCE
Corresponding Author Secondary Information:	
Corresponding Author's Institution:	Hospices Civils de Lyon
Corresponding Author's Secondary Institution:	
First Author:	Caroline Froment Tilikete
First Author Secondary Information:	
Order of Authors:	Caroline Froment Tilikete
Order of Authors Secondary Information:	
Funding Information:	
Abstract:	<p>Eye movements serve vision in orienting gaze toward an object of interest in order to place its image simultaneously on both foveas and in stabilizing gaze relative to the environment in order to maintain fixation on the object of interest, even in the case of body displacement. Disorders of eye movements can interfere with ocular alignment and/or monocular motility, and result in diplopia, which is the most common symptom. Eye movement disorders can also interfere with binocular motility without ocular misalignment and result in gaze palsy. Finally, disorders of eye movement can interfere with ocular stability during fixation or body displacement and result in oscillopsia. A systematic examination of eye movements should be part of the neurological exam in order to detect asymptomatic manifestations that can help for the diagnosis in multiple neurological pathologies. In case of eye movement disorders, the goals of the examination are to precisely characterize the disorder of motility, alignment or stability, in order to finally localize anatomically the lesion among the peripheral ocular motor system or the more complex central eye movement neural network and suggest mechanisms and etiologies.</p> <p>In this review, we are describing the standard methods of ocular motor examination, including a 'general' approach to any ocular motor assessment, and also the specific approaches to evaluating ocular misalignment, difficulty moving both eyes, and finally unstable gaze. This article will include practical tips on how to perform the tests most effectively or how to interpret the clinical signs elicited.</p>
Response to Reviewers:	<p>Dear editor and reviewer, Thank you for your proposal. I made corrections according to all comments. I hope this will be fine for you. Sincerely Caroline Froment</p>

HOW TO ASSESS EYE MOVEMENTS CLINICALLY

Caroline Froment Tilikete

Hospices Civils de Lyon, Groupe Hospitalier Est, Hôpital Neurologique, Service de Neuro-Ophtalmologie 59 Bd
Pinel, 69377 Bron Cedex ; Université Claude Bernard Lyon I; Centre de Recherche en Neurosciences de Lyon,
INSERM U1028, CNRS UMR5292, IMPACT Team

caroline.froment@inserm.fr

Declaration: not applicable

HOW TO ASSESS EYE MOVEMENTS CLINICALLY

Abstract

Eye movements serve vision in orienting gaze toward an object of interest in order to place its image simultaneously on both foveas and in stabilizing gaze relative to the environment in order to maintain fixation on the object of interest, even in the case of body displacement. Disorders of eye movements can interfere with ocular alignment and/or monocular motility, and result in diplopia, which is the most common symptom. Eye movement disorders can also interfere with binocular motility without ocular misalignment and result in gaze palsy. Finally, disorders of eye movement can interfere with ocular stability during fixation or body displacement and result in oscillopsia, which is an illusion of an unstable visual world.

A systematic examination of eye movements should be part of the neurological exam in order to detect asymptomatic manifestations that can help for the diagnosis in multiple neurological pathologies. In case of eye movement disorders, the goals of the examination are to precisely characterize the disorder of motility, alignment or stability, in order to finally localize anatomically the lesion among the peripheral ocular motor system or the more complex central eye movement neural network and suggest mechanisms and etiologies.

In this review, we are describing the standard methods of ocular motor examination, including a 'general' approach to any ocular motor assessment, and also the specific approaches to evaluating ocular misalignment, difficulty moving both eyes, and finally unstable gaze. This article will include practical tips on how to perform the tests most effectively or how to interpret the clinical signs elicited.

Keywords : diplopia, ocular motor palsy, gaze palsy, nystagmus, oscillopsia, saccadic intrusions

1. The 'general' approach to any ocular motor assessment

1.1. History

Three main symptoms might be asked for in the 'general' approach to any ocular motor assessment. Diplopia suggests acquired ocular misalignment, which can result from dysfunction of the extra-ocular muscles, neuromuscular junction, ocular motor nerves, ocular motor nuclei or internuclear pathways. Gaze palsy without diplopia suggests conjugate binocular involvement which can be due to peripheral symmetrical extra-ocular muscle or neuro-muscular junction involvement; multiple ocular motor nerve involvement or from nuclear and supranuclear involvement. Finally, oscillopsia suggests acquired ocular instability due to nystagmus, saccadic intrusions, other abnormal eye movements or abnormal vestibulo-ocular reflex (1).

Taking the history is sometimes more tricky. The patient may be poorly informative when his/her main complaint is unspecific 'blurred' vision. In this case, asking if one eye closure improves the blur suggests binocular diplopia, while the oriented history asking for moving images can disclose oscillopsia.

However eye movement disorders may be asymptomatic, and in those cases a systematic eye movement examination is needed. Asymptomatic but clinically obvious ocular motor disorders are a cardinal aspect of congenital or infantile disorders such as infantile strabismus or infantile nystagmus (2). However, some patients with infantile strabismus or congenital ocular motor palsy may present with a new symptom of diplopia when reaching adulthood and the clinical challenge is to demonstrate the absence of any associated acquired disorder. Some acquired disorders do not disturb vision either because they appear in eccentric gaze (i.e. gaze-evoked nystagmus or supranuclear upward vertical gaze palsy), because of a very progressive and symmetrical palsy such as in chronic progressive extra-ocular muscles palsy or because the ocular instability does not reach the velocity threshold for perceiving oscillopsia. For some eye movement disorders however, such as in internuclear ophthalmoplegia in multiple sclerosis, the lack of symptoms remains unexplained.

In any cases, the history has to search for:

- history of infancy strabismus, amblyopia, eye patching, abnormal head posture and small eye
- age, vascular risk factors, treatments
- onset: acute, subacute, progressive
- evolution: resolving, fluctuating, chronic
- associated pain, ophthalmological or neurological symptoms

1.2. Examination

1.2.1. Ocular stability

The patient should be examined first with the eyes in primary position of gaze, while looking at a small object located in front of him (Box 1). In primary position of gaze, the fixation can be interrupted by drifts, nystagmus or saccadic intrusions that are defined in table 1. In some cases of high velocity pendular nystagmus, the clinical distinction with saccadic oscillations can be tricky and eye movements recording may help in defining the underlying pathological eye movement. The presence of nystagmus during fixation in primary position of gaze is always pathological. Saccadic intrusions such as square wave jerks (see part 4.2.3) can be seen in normal individuals, particularly in the elderly (Box 2) (3).

In a second step, the ocular stability of one eye might be observed while the examiner occludes the other eye; this procedure might be repeated on each eye (4).

Practical tip. The presence of a jerk horizontal nystagmus beating toward the viewing eye during monocular fixation, is pathognomonic of a latent nystagmus (infantile nystagmus). It can be associated with an upward deviation of the covered eye that is called dissociated vertical deviation.

In a final step, ocular stability might be looked when the patient fixates 20° to the right, left, up and down and in convergence. Gaze-evoked nystagmus is specifically triggered in eccentric gaze and **consists in centripetal slow phases followed by centrifugal quick phases**. It has to be differentiated from end-point nystagmus seen in extreme lateral gaze (30° to 40°) in normal individuals that usually stops with prolonged lateral gaze (Box 2) (5).

The following clinical steps regarding examination of an abnormal eye movement will be further described in part 4.

1.2.2. Ocular alignment

In the context of the 'general' ocular motor assessment, the examination of ocular alignment might be limited to the observation of manifest ocular deviation (or strabismus) in primary position of gaze. The terminology used to designate the different types of ocular deviations will be further developed in part 2.

1.2.3. Ocular motility

The examination of ocular motility is performed in assessing the amplitude of ductions (monocular eye movements during occlusion of the other eye) and versions (binocular eye movements in the same direction). Ductions and versions are tested by asking the patients to look at eight positions of gaze (Figure 1). The examiner is searching for any limitation of amplitudes of one or both eyes, that persists despite vigorous encouragement (4, 6). In case of duction and version deficit, the following clinical steps regarding the eye movement examination will be further described in parts 2 and 3.

1.2.4. Examination of eye movements

The patient should then be evaluated for the integrity of the different types of eye movements.

Smooth pursuit can be examined by asking the patient with the head still, to track a small target, such as a pencil or a finger, held at one meter and moved slowly horizontally and vertically. Other tools are useful (Figure 2A). This stimulation should induce smooth eye tracking. The observation of catch-up saccades suggests impaired smooth pursuit, which is often described as “jerky pursuit” or ‘broken pursuit’. It is noticeable that normal smooth pursuit depends on the patient’s age and ability to direct attention, and on the direction of stimulation. Vertical smooth pursuit is much less efficient than horizontal, mainly for downward tracking (7) (Box 2). Striped tape and optokinetic drum stimulate horizontal or vertical smooth pursuit and/or optokinetic nystagmus.

Practical tip. Hand held optokinetic drums or striped tape can be useful tools for demonstrating pursuit or optokinetic asymmetries or reversal (seen in some congenital nystagmus) or absent quick phases (or reflexive saccades).

Convergence is evaluated by having the patient look at any target that is brought gently toward their nose, along the sagittal plane (Figure 2B). Looking at their own thumb might help to elicit convergence. The normal response is adduction of both eyes combined with pupillary constriction and accommodation (near triad). Convergence insufficiency is a very common benign disorder among teenagers and the elderly (Box 2). Convergence can elicit ocular instability in some patients (see part 4.2).

Oculocephalic responses can be evaluated by having the examiner gently rotate the head horizontally then vertically, while the patient is fixating a stationary target such as the examiner’s nose (Figure 2C). The inputs triggering stabilizing eye movements come from the vestibulo-ocular reflex, the visual system and the proprioceptive afferents in the neck (8).

Practical tip. The main interest of oculocephalic responses in clinical assessment of eye movements is when limited eye movements (saccades) can be overcome by oculocephalic stimulation, suggesting central (supranuclear) or non-organic origin.

Evaluation of the oculocephalic responses can be completed by asking the patient to fixate a target moving simultaneously with the head rotation (Figure 2C); the expected cancellation of the vestibulo-ocular reflex by fixation can be lacking, leading the eyes to correct the fixation with small catch-up saccades.

Practical tip. There is one situation in which oculocephalic responses are jerky: in case of association of jerky smooth pursuit (due to cerebellar dysfunction mainly) and deficit of vestibularly driven eye movements (due to vestibular deficit). This association of cerebellar dysfunction and vestibular deficit is observed mainly in Cerebellar ataxia, neuropathy and vestibular areflexia syndrome (CANVAS) (9). In these patients, there are catch-up saccades with head impulse test, but the VOR suppression shows a much less jerky VOR response as there “is no VOR to suppress.

Finally, the saccades should be examined by asking the patient to fixate a central target (i.e. the examiner’s nose) then a peripheral target (i.e. the examiner’s finger or the tip of a pen) and back (Figure 2D). Saccades in each direction and in vertical and horizontal plane should be checked. This bedside examination allows analyzing velocity, initiation (latency), accuracy and conjugacy of saccadic eye movements (10). Saccadic slowing is easily detected by clinical examination: normal saccades do not allow the examiner to catch the eye movement but only the change of ocular fixation.

Practical tip. Slow vertical saccades are more specific than limited amplitude, for example to differentiate Parkinson’s disease from progressive supranuclear palsy. Slow adducting saccade, lagging the contralateral abducting eye can be a useful clinical sign to detect mild internuclear ophthalmoplegia.

The latency of saccade initiation is defined as the delay taken by the patient before moving the eyes following a verbal or a visual stimulation; global increase or asymmetries of latencies may be clinically noted. Finally, saccades can be inaccurate, either hypometric or hypermetric leading respectively to forward or backward correction that is easily detected clinically. Saccadic hypometria is a frequent observation in normal subjects (4) (box 2). **However, the saccades rapidly become accurate throughout the testing.** If saccade abnormalities are detected, the following steps of examining eye movements are further described in part 3.

1.3. Additional aspects

Beside the eye movement examination, the examiner should always consider measurement of corrected visual acuity, a simple confrontation assessment of the central and peripheral visual field, assessment of pupils and levator palpebrae and orbicularis muscles, optic discs (papilloedema), orbits (especially globe displacement in any plane) and frontalis overaction.

2. Assessing the patient with ocular misalignment

Ocular misalignment associated with diplopia may be secondary to a dysfunction of the extraocular muscles, neuromuscular junction, cranial nerves or central oculomotor pathways. The clinical steps of ocular examination should orient the topographical diagnosis.

2.1. History

The consequence of misalignment of the visual axis should be binocular diplopia, that is explained by the noncorresponding area where the seen object falls on the two retinas (4). Diplopia is lacking in patients with ocular misalignment due to childhood strabismus with amblyopia. Thus it is important to enquire about any history of strabismus, eye patching or abnormal head posture. Occasionally patients with ocular misalignment do not complain of diplopia because of defective visual function in at least one eye, unilateral ptosis or neutralization of the second image due to large angle strabismus (8). Some patients are mainly complaining of blurred vision, and asking or testing whether monocular viewing improves their vision is helpful in this regard.

Patients with diplopia should first be asked whether their double vision is binocular or monocular. Binocular diplopia resolves when the patient closes either eye, while monocular diplopia persists when the patient closes one eye.

Practical tip. Monocular diplopia is (almost) never related to a neurological disorder and is most commonly explained by refractive errors, ocular diseases (i.e. cataract) or anorganic disorders. Binocular diplopia often reveals an underlying neurologic disorder.

Patients with binocular diplopia should then be asked whether the diplopia is horizontal (suggesting dysfunction of the horizontal recti), vertical or oblique (suggesting dysfunction of the vertical recti and/or oblique muscles). In the latter case, one image may be tilted relative to the other. The patients may be then asked whether diplopia is worsened in some specific gaze direction and/or for near or distant viewing. Indeed, the double vision will increase when the patient is looking in the direction of action of the paretic muscle. For example, in right lateral rectus dysfunction, the horizontal diplopia is worsening in right and distant viewing.

The history should finally determine the modalities of evolution: stable, resolving, increasing or fluctuating over time.

2.2. Examination

The different steps useful to examine patients complaining of diplopia are summarized in table 2.

2.2.1. Recognize any limitation of eye movements: ductions and versions tests

The first step of the ocular motor examination in cases of ocular misalignment (and diplopia) is to recognize any limitation of eye movement by assessing the amplitude of ocular motility in the direction of action of all six extraocular muscles (see part 1.2.2). Figure 1 illustrates the main action of the extraocular muscles that might be clinically evaluated. First test ductions by examining one eye with the other covered and then versions by examining both eyes together.

Practical tip. When adduction of one eye is obviously limited in lateral gaze, look for preserved adduction during convergence (a dissociation indicates a central origin i.e. in internuclear ophthalmoplegia).

Sometimes it can be useful to evaluate whether eye movement limitation is due to muscle weakness or mechanical restriction of the muscle by using the forced duction test. In this test the examiner applies topical anesthesia in one eye then attempts to move the eye by pulling it (with forceps) or pushing it (with cotton-tipped). A positive duction test (inability to move the eye passively) suggests mechanical restriction.

2.2.2. Recognize and characterize a small ocular misalignment

If examination of ductions and versions does not show any obvious limitation of eye movements, the demonstration and the characterization of a small ocular misalignment may require the use of the cover test, the red glass and/or the Maddox rod test. Note that these tests detect relative ocular deviations but do not identify the paretic eye. They might help to recognize the misalignment and ascertain whether it is comitant (same amount of deviation in all gaze directions) or incomitant (increased in the direction of the paretic extra-ocular muscle).

2.2.2.1. Recognize a small ocular misalignment

Cover tests are helpful to demonstrate a small ocular misalignment. They are based on the prediction that if the visual axis is not aligned with the target, then an eye movement (saccade) will be performed by the patient to foveate the presented target. It is the detection and the estimation of the size of this corrective saccade that indicates the misalignment of the visual axis to the clinician. The patient can also verbally describe the change in the position of the target, from one condition of covering to the other. The use of a translucent occluder may be useful for the examiner to observe the movements of the covered eye.

Two cover tests may be used. The cover-uncover test discloses heterotropia or ocular deviation with binocular fixation (or manifest ocular deviation). The cross cover test (or alternate cover test) discloses heterophoria or ocular deviation when binocular fixation is disturbed (or latent ocular deviation). The examination should begin with the cover-uncover test (Figure 3A). If the cover-uncover test does not demonstrate ocular misalignment (the subject is said orthotropic), then proceed to the cross-cover test to demonstrate heterophoria (Figure 3B). In both tests an outward movement denotes esotropia(phoria), an inward movement exotropia(phoria). For vertical downward or upward movement, the term hypertropia(phoria) is preferred to denote the deviation of the higher eye whatever the direction of corrective saccade. In the absence of heterophoria, the patient is said orthophoric (i.e. there is normal ocular alignment preserved under monocular or binocular viewing conditions). Exophoria is very common in normal individuals, and may be considered as physiological unless the misalignment varies in different gaze directions (Box 2).

2.2.2.2. Characterize a small ocular misalignment

The red glass test and the Maddox rod tests should be then used to reliably characterize the disparity between retinal images. These tests are based on the subjective allocation of a target position in space by the patient when dissociating the viewing of a target by the use of colored glass, placed by convention over the right eye (Figure 4). The Maddox is of greater value than the red glass test when the eyes are deviated in two planes.

In case of vertical misalignment, the four steps test (Table 3) helps to differentiate superior oblique deficit from other causes (4). Right superior oblique deficit would present as right hypertropia, which increases while looking to the left and down and with head tilt on the right side. A fifth step might be useful in non-conclusive four steps test. It consists in measuring vertical deviation in flat position: a decrease in the vertical deviation of at least 50% in this position is indicative of skew deviation (11, 12).

Practical tip. Skew deviation can be associated to ipsilateral head tilt, ipsilateral ocular torsion (that can be seen on fundi) and tilt of subjective visual vertical in the context of ocular tilt reaction.

In case of paroxysmal diplopia, the examination should check for superior oblique myokymia (cf part 4) and ocular neuromyotonia (13).

Practical tip. For ocular neuromyotonia, search for a tonic spasm by asking the patient to maintain eccentric gaze for at least 10 sec. Repeat the procedure in all 4 horizontal and vertical directions.

At the end, the examiner should be able to determine whether ocular misalignment maps to one or multiple extra-ocular muscles, to a cranial nerve or to central dysfunction. The examination should also look for additional aspects as developed in paragraph 1.3.

2.3. Topographical diagnosis

The presence of orbital signs such as proptosis, periorbital edema, chemosis, deviation of the ocular globe, mechanical restriction of the eye movement, pain, possible visual loss with optic neuropathy (in the latter case, it defines the orbital apex syndrome) suggest that the problem lies in the orbit and/or involves the extraocular muscles themselves (14). If carotid-cavernous fistula is suspected, use the stethoscope placed over the patient's temple or orbit to detect any cranial bruit. The presence of fluctuating ptosis and/or binocular diplopia, worsening after exercise, weakness of the orbicularis muscle and fluctuation during the examination is very suggestive of ocular myasthenia (15). If the symptoms are compatible with ocular motor nerve involvements, the association of unilateral symptoms with deficit in V1 territory is very suggestive of cavernous sinus syndrome (16). Bilateral involvements of the ocular motor nerves are more suggestive of subarachnoid localization of the pathology. Finally, the association with neurological signs orients toward the brainstem.

3. Assessing the patient with difficulty to move both eyes

Conjugate gaze deficit may be secondary to a symmetrical dysfunction of the extraocular muscles (such as myopathy) or neuromuscular junction (ocular myasthenia), combined involvement of bilateral ocular motor nerves (such as Miller Fisher syndrome), nuclear, supranuclear palsy or oculomotor apraxia. The clinical steps of ocular examination should help to orient the topographical diagnosis.

3.1. History

Even with acute deficit, most patients with conjugate gaze deficit do not complain of clear limitation to gaze sideways or vertically. They will offer vague visual complaints such as blurriness or dizziness, sometimes reading disorders with downward gaze palsy or horizontal saccadic palsy(17). Some patients may be asymptomatic and the conjugate gaze deficit is only detected on examination.

The patient should be asked if the gaze disorder occurred acutely or whether this is a progressive longstanding disorder. The horizontal versus vertical direction of gaze palsy is also clinically relevant. The patient might be

asked for associated ptosis, limb weakness, stiffness, ataxia and falls, and bulbar signs (difficulties in swallowing, chewing, breathing...).

3.2. Examination

The patient might be checked for the different types of eye movements, by testing first reactive saccades (such as described in part 1.2.3), and analyzing amplitude, velocity, initiation and accuracy.

If reactive saccades are limited in amplitude or hypometric, it might be relevant to check large amplitude ($>60^\circ$) saccades to determine whether the patient is using head thrust to compensate for gaze deficit or whether there is an aspect of stair case saccades (Figure 6).

If there is a gaze limitation, the second step is to determine whether slow eye movements are preserved, by testing first smooth pursuit and second oculocephalic reflex (Figure 2). Testing Bell's phenomenon by holding the lids of the patient while asking him/her to attempt to close his/her eyes can also help to demonstrate the preservation of vertical slow eye movements in case of upward saccadic palsy (8, 18).

If all three types of eye movements are limited, the lesion can involve extra-ocular muscle, junction, cranial nerves, ocular motor nuclei or pretectum. Restriction of ocular elevation, with proptosis and lid retraction is more suggestive of thyroid-associated ophthalmopathy (6). In case of symmetrical involvement of horizontal and vertical eye movements, look for signs of muscular involvement. Associated ptosis, weakness of eye closure and proximal weakness of limbs are suggestive of chronic progressive external ophthalmoplegia in case of insidious involvement or myasthenia gravis if subacute. Associated ataxia and tendinous areflexia might be looked for in case of acute or subacute bilateral ophthalmoplegia, suggesting then Miller Fisher syndrome (19). In case of conjugate horizontal gaze palsy, the preservation of convergence is pathognomonic of abducens nuclear syndrome.

If only saccades are limited or slowed, with preservation of the amplitude of slow eye movements as tested by smooth pursuit and the oculocephalic reflex, the lesion is thought to involve supranuclear structures. It might be then useful to test for the quick phase of nystagmus (reflexive saccades) in order to differentiate supranuclear palsy from oculomotor apraxia. Quick phases of nystagmus can be examined by spinning the patient in a rotating chair to elicit vestibular nystagmus or by using an optokinetic drum to elicit optokinetic nystagmus (Figure 2). The lack of preservation of quick phases is indicative of supranuclear palsy and points toward an involvement of the premotor saccadic neurons in the brainstem. In supranuclear palsy, dissociation between horizontal and vertical

saccades is usually found. In Progressive Supranuclear Palsy, the vertical supranuclear palsy is often associated with saccadic intrusions (square waves), lid opening apraxia or blepharospasm. Preservation of quick phases is indicative of oculomotor apraxia and points toward an involvement of neural saccadic circuits above the brainstem (20). In the congenital or inherited forms of oculomotor apraxia, the association of stair-case saccades (Figure 5) and compensating head thrust are frequent (21). In the acquired forms, it might be then relevant to check whether patients present some dissociation in the ability to produce reactive versus volitional saccades. Reactive saccades are generated by the appearance of unexpected novel objects seen or heard. Volitional saccades on the other hand are made as part of purposeful behavior, such as visual searching, reading, or simply on command. At bedside, reactive saccades are examined by asking the patient to make saccades toward moving finger; and volitional saccades by asking the patient to look on command to the right, left, up and down (without visual target). Deficit of volitional saccades would suggest frontal lobe involvement, while reactive saccade disturbances suggest parietal lobe involvement.

Antisaccades examination might be relevant to disclose a subtle dysfunction of the frontal cortical areas (i.e. in Progressive Supranuclear Palsy). The patient is asked to fixate a central target (i.e. the examiner's nose) while the examiner presents two fingers 20 deg apart from the central position of gaze. When the examiner is shaking one finger, the patient is asked to look in the opposite direction, toward the non-moving one. This procedure might be repeated around ten times to determine the number of erroneous saccades (made toward the moving finger) in percentage.

4. Assessing the patient with unstable gaze

There are two different conditions of unstable gaze. The gaze instability can occur with a stable head, due to abnormal eye movements such as nystagmus, saccadic intrusions or other types of ocular tremor. The gaze instability can also specifically occur during head movements, due to deficit of the vestibulo-ocular reflex.

4.1. History

Unstable gaze results in movement of the image on the retina, causing oscillopsia and deterioration of visual acuity. Oscillopsia is a perception of an unstable vision, made of to and fro movement of the environment, which can be side to side or up-and-down (1). Patients can however complain of vague symptoms such as blurred vision and/or reading difficulties. Oscillopsia is however lacking in cases of ocular instability developing in blindness or in case of infantile nystagmus. History should therefore ask for the longstanding or recent occurrence of gaze instability. Oscillopsia can also be lacking in some acquired nystagmus occurring in eccentric gaze.

In case of oscillopsia, the patient should be asked whether it occurs with head still or during head displacements, in primary position of gaze or in eccentric gaze, in viewing far or near objects. Oscillopsia (or blurred vision) occurring during head and body displacement is pathognomonic of (mainly bilateral) vestibulo-ocular reflex deficit (22). The patient should therefore be asked for any history of associated postural instability. Previous vertigo events are usually lacking in case of bilateral vestibular deficit. Whether oscillopsia is vertical or horizontal, monocular or binocular are relevant information. Paroxysmic monocular vertical oscillopsia is pathognomonic of superior oblique myokymia. In cases of head tilt, ask for old photographs. Always document the current patient's medications.

4.2. Examination

Examination of ocular stability should first follow the steps described in part 1.2.1.

4.2.1. In cases of jerk nystagmus or vestibular syndrome

If the patient demonstrates jerk nystagmus during fixation, define the direction (horizontal, vertical, torsional or mixed) of eye movement, the beating direction (direction of quick phase), the effect of gaze direction and the effect of fixation. In peripheral vestibular disorders, the nystagmus is mainly horizontal and torsional, increases with gaze in the direction of quick phases and beats away from the pathologic side. The peripheral nystagmus is

better seen under removal of fixation by using Frenzel goggles or the ophthalmoscope. With ophthalmoscope, while viewing the optic disk in one eye, the examiner detects any ocular instability first during fixation with the fellow eye, then without fixation by occluding the fellow eye (23). In central vestibular disorders, the nystagmus is frequently purely vertical or torsional, and is not modified by removal of fixation. Check for difference in amplitude (dissociated nystagmus) and direction (disconjugate nystagmus) of ocular instability in each eye, by looking at the bridge of the patient's nose (4). Dissociated and disconjugate nystagmus are mainly seen in central disorders.

If both the patient complains of vertigo and the examination does not disclose spontaneous nystagmus, triggering maneuvers should be used (Table 4). Mixed horizontal torsional nystagmus induced by horizontal head shaking test is very suggestive of unilateral peripheral vestibular disorder but it can also occur in central vestibular disorders (24, 25). Hyperventilation induced nystagmus is very suggestive of a vestibular schwannoma (26). Valsalva induced nystagmus is suggestive of Arnold-Chiari malformation, perilymph fistula or superior semi-circular canal dehiscence syndrome (4). The Dix-Hallpike maneuver (Figure 6) should be tested in the case of **paroxysmal** positional vertigo: the presence of a transient geotropic vertical torsional nystagmus is very suggestive of benign paroxysmal positional vertigo.

In case of obvious horizontal jerk nystagmus, observe any reversal during sustained examination over 2 to 3 minutes, for periodic alternating nystagmus (27). If the horizontal nystagmus is only observed in lateral gaze, check whether it is binocular and in only one direction, suggesting vestibular nystagmus, reversing in each direction of gaze, suggesting gaze-evoked nystagmus or monocular in the abducting eye, suggesting internuclear ophthalmoplegia (as demonstrated by associated adduction palsy or slowing). In cases of gaze evoked nystagmus, check whether a transient reversing nystagmus occurs when returning to the central position, suggesting rebound nystagmus (4). In case of disconjugate jerk nystagmus beating to the nose in patients with pretectal syndrome, check whether attempted upward saccades (that can be more easily elicited by downward optokinetic stimulation) increases the nystagmus, which corresponds to convergent-retraction nystagmus (28).

Discrete downbeating nystagmus is mostly observed in lateral and downward gaze and is often associated with **jerky** smooth pursuit and loss of visual cancellation of the oculocephalic reflex (29). Upbeating nystagmus can be observed in upgaze, suggesting vertical gaze evoked nystagmus that is often accompanying bilateral internuclear ophthalmoplegia. If upbeat nystagmus is observed in primary position of gaze, it might be relevant to check whether the nystagmus slows down or even reverses in laying the patient flat (29).

Disconjugate vertical nystagmus, either jerk or pendular is pathognomonic of see saw nystagmus and should be accompanied by a conjugate torsional component (30, 31).

4.2.2. In cases of pendular nystagmus

The main etiologies of acquired pendular nystagmus are multiple sclerosis (MS) and oculopalatal tremor following brainstem stroke (32). The frequency, amplitude, conjugacy and direction may help to distinguish between these etiologies (Figure 7). Convergence should also be checked in patient with MS, to look for convergence-evoked pendular nystagmus (33). In brainstem stroke, pendular nystagmus is part of the oculopalatal tremor, which can be demonstrated by the observation of synchronous tremor of the palate and branchial muscles (34, 35).

4.2.3. In cases of saccadic intrusions

The examination should help to differentiate the various forms of saccadic intrusions (Figure 8) (36). One may distinguish two main types of saccadic intrusions by the presence or absence of an intersaccadic interval (ISI), a latent period that usually lasts 180–200ms between sequential saccades (36). Saccadic intrusions with a normal intersaccadic interval include square wave jerks (SWJs), square wave pulses (SWPs or macrosaccadic square wave jerks), macrosaccadic oscillations and saccadic pulses. The latency and amplitude of to and fro saccades can differentiate square waves (200 ms, < 4 deg) from square wave pulses (80 ms, > 5 deg). Macrosaccadic oscillation is made of a run of saccades following change of fixation in a crescendo-decrescendo pattern, respecting a 200 msec interval (4, 8). Saccadic pulses are brief saccadic intrusions that take the eye away from the fixation point, and are immediately followed by a slow glissadic drift to the previous position (36). Saccadic intrusions without intersaccadic interval include ocular flutter and opsoclonus. Ocular flutter consists of back-to-back horizontal saccades while opsoclonus (or saccadomania) is made of multidirectional saccades of varying amplitudes. Although flutter is suggestive of severe neurologic disorders, it can be voluntary or anorganic in some normal subjects: this phenomenon is called anorganic or voluntary flutter (37).

Practical tip. In patients visually complaining of saccadic oscillations, distinguishing patients with a pathological versus voluntary/anorganic origin may be sometimes tricky. In the voluntary/anorganic flutter, the abnormal eye movement is not sustained, is often accompanied by convergence effort, facial grimacing or eyelid flutter. In the pathological flutter, there is most often associated ataxia and myoclonus.

4.2.4. In cases of monocular oscillopsia

Paroxysmal monocular oscillopsia is mainly suggestive of superior oblique myokymia (38). The clinical demonstration of the monocular tremor may be difficult. The attacks are brought by looking downward, tilting the head toward the affected eye or blinking. Due to its small amplitude, vertical and torsional tremor is better seen on the conjunctival vessels, and more easily detected with an ophthalmoscope or slit lamp (23).

4.2.5. In cases of oscillopsia during head and body displacements

In that case, the vestibulo-ocular deficit should be clinically evaluated. To test the vestibulo-ocular reflex, one may use high frequency head movements, as triggered by the head impulse test (Figure 9) (39). This test is very helpful to distinguish peripheral from central vestibulo-ocular deficit (40). Comparing near visual acuity in static versus dynamic condition (2 Hz to and fro rotation of the head) also helps to determine the efficiency of the VOR; in a normal subject the visual acuity will decrease only one or two lines on a Snellen chart, whereas in patients with VOR hyporeflexia visual acuity will decrease more dramatically (41).

BOXES

Box 1. How to perform examination of ocular stability

1. Always assess ocular stability with binocular then monocular viewing
2. Always assess ocular stability in primary position of gaze, in eccentric gaze and in convergence
3. Look at pupil for horizontal or vertical instability
4. Look at conjunctival vessels for instability in the torsional plane
5. Look at lids to detect small amplitude vertical ocular instability
6. In case of tiny ocular instability, check
 - a. optic disc stability through the ophthalmoscope placed in front of one eye while the other eye is fixating
 - b. ocular stability using magnification such as Frenzel goggles

Box 2. Abnormal eye movements possibly observed in normal subjects.

- Square wave jerks (< 20/mn)
- End-point nystagmus (> 30° of eccentricity)
- Jerky downward pursuit
- Convergence insufficiency
- Hypometria of horizontal saccades **when you first begin to test saccades**
- Hypermetria of downward centripetal saccades
- Comitant exophoria

TABLES

Table 1. Definition of the different types of abnormal eye movements

1. Ocular drifts: unregular small amplitude eye movement, mainly observed in blind patients.
2. Nystagmus : regular to-and-fro eye oscillations initiated by a slow eye movement (slow phase)
 - a. Jerk form : slow phase followed by a corrective saccade named quick phase
 - b. Pendular form: slow-phase oscillations without quick phases
3. Saccadic intrusions: fast eye movements that interrupt fixation, ranging from isolated saccades to sustained saccadic oscillations.

Table 2. The main steps of examining a patient with binocular diplopia

1. Recognize limitation of eye movement using duction and version tests
2. In some cases of obvious limitation, use the forced duction test
3. In case of no obvious limitation of eye movements, demonstrate ocular misalignment :
 - a. heterotropia by using the cover-uncover test
 - b. in case of orthotropia, heterophoria by using the cross cover test
4. In case of small ocular misalignment, characterize the disparity between retinal images by using the red glass and/or the Maddox rod test
5. In case of vertical misalignment
 - a. Use the 4 steps test
 - b. Use the lying test

Table 3. The four steps test for vertical diplopia

1. Step 1 determines the side of hypertropia in primary position.
2. Step 2 determines whether hypertropia increases in right or left gaze.
3. Step 3 determines whether hypertropia increases in up or down gaze.
4. Step 4 determines whether the hypertropia increases on right or left head tilt.

Table 4. Triggering maneuvers for vestibular nystagmus

1. During suppression of visual fixation (using Frenzel goggles or ophthalmoscopy)
2. Following head-shaking test, by asking the patient to vigorously shake the head for 10 to 15 sec side to side, then up and down
3. Following a sustained (30 sec) hyperventilation
4. During Valsalva maneuver.
5. In the Dix-Hallpike maneuver

FIGURE LEGENDS

Figure 1. Examination of versions in 8 positions of gaze in a normal subject and corresponding action of extraocular muscles. For ductions examination, same procedure with occlusion of one eye.

Figure 2. The different steps of examining ocular motility. A. Smooth pursuit. The patient tracks a small target. In uncooperative patients, a large mirror slowly rotating can help to trigger smooth pursuit. Optokinetic drum does stimulate horizontal or vertical smooth pursuit and/or optokinetic nystagmus, with a slow phase in the direction of the stimulus and a corrective quick phase. B. Convergence stimulation. C. The oculocephalic reflex and cancellation by fixation tests. D. Examination of reactive saccades.

Figure 3. Cover tests. For each of the tests, the eyes are tested in primary position of gaze, then in the eight cardinal positions, by rotating the patient's head relative to a target that is fixed in space. The patient is instructed to fixate first a distant target (6 m) then a near target (35 cm). A. The cover-uncover test. Cover the right eye and look for any saccade of the uncovered left eye. Then cover the left eye, and look for any saccade of the uncovered right eye. The direction of the corrective saccade must be noted. If a saccade is noted repeatedly in the same direction, it demonstrates a manifest misalignment or a 'tropia'. B. The cross-cover test. The occluder is rapidly shifted from one eye to the other (to prevent binocular viewing) with a 1 sec pause between each transfer: this has to be done for 10 to 20 sec since deviation may grow over time of examination. Any corrective saccade that is noted repeatedly in the same direction for each eye demonstrates a latent misalignment of a 'phoria'.

Figure 4. The red glass test and the Maddox rod tests. In the red glass test, the patient sees a red dot with the right eye. In the Maddox rod test, the patient sees a red line, which can be horizontal if the cylinders are oriented vertically or vertical if the cylinders are oriented horizontally. A. The patient is instructed to stare straight ahead a bright light, and to describe if he/she sees the two images aligned or separated, and to determine the relative extent of separation in horizontal and vertical planes, in the cardinal positions of gaze. B. In case of exotropia or exophoria, the red image is crossed, i.e. appearing to the left of the white dot. C. In case of esotropia or esophoria, the red image is uncrossed, i.e. appearing to the right of the white dot. D. With a right hypertropia, the red image will appear below the white dot. E. With a left hypertropia, the red image will appear above the white dot.

Figure 5. Stair-case saccades. As shown in this plot of horizontal eye position in time, multiple small saccades are required to reach the target. This pattern, called stair-case saccades, has been mainly described in the congenital or inherited forms of oculomotor apraxia (courtesy of Muriel Panouillères).

Figure 6. The Dix-Hallpike Maneuver. The patient sits on the examination table and the head is turned 45° horizontally. The head and trunk are quickly brought straight back so that at the end, the head is hanging over the edge of the examination table by 45°.

Figure 7. Aspect of pendular nystagmus. In oculopalatal tremor following brainstem stroke, the pendular nystagmus is of low frequency (less than 3 Hz), high amplitude, dysconjugate and most often vertical. In multiple sclerosis, the nystagmus is of high frequency (4 to 6 Hz), low amplitude and mostly horizontal. It is often conjugate, although monocular vertical pendular nystagmus can be observed.

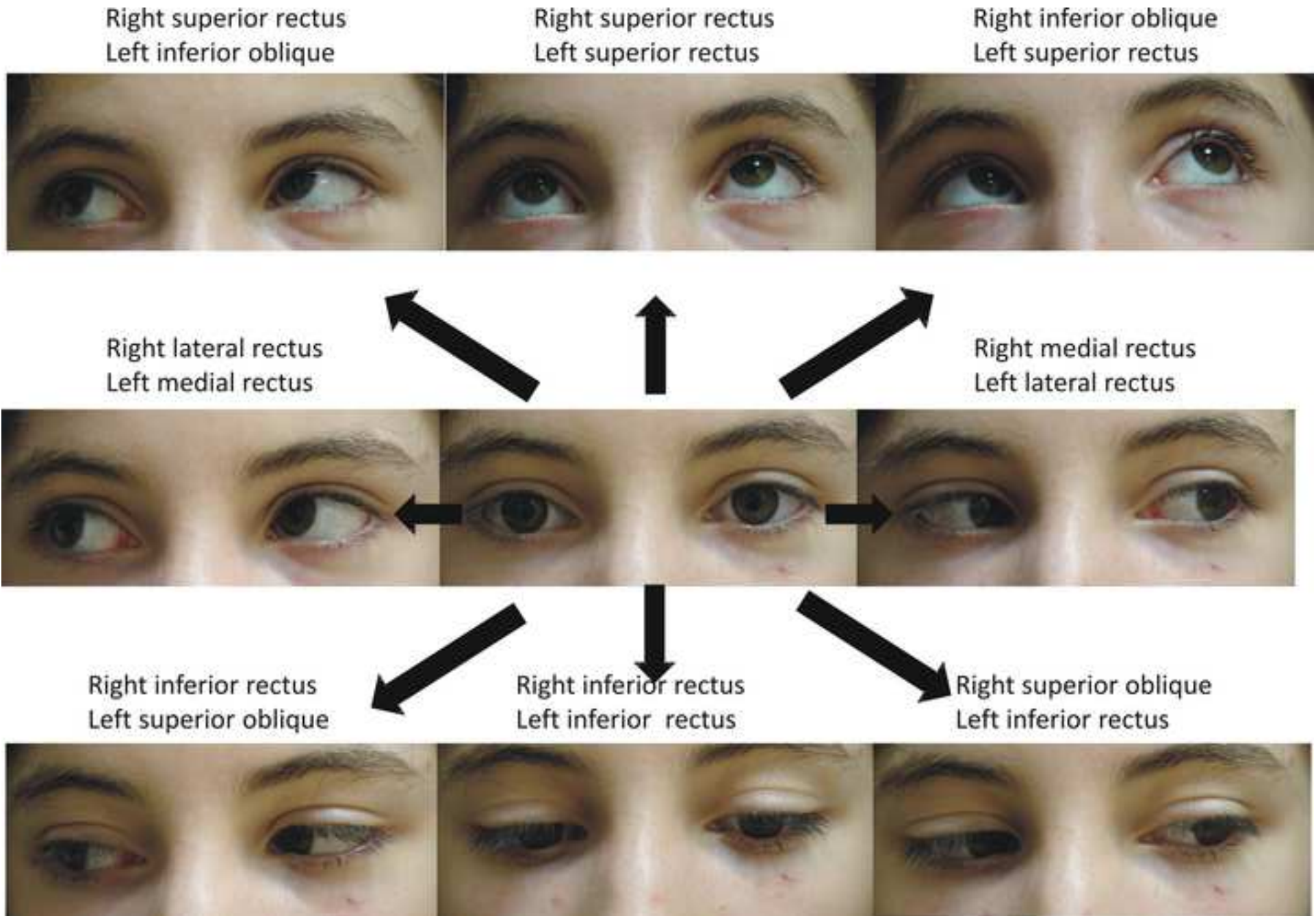
Figure 8. How to differentiate the different forms of saccadic intrusions. Square wave jerks are the most common type of saccadic intrusions and consist of small conjugate couplets of horizontal back-to-back saccades ranging from 0.5 deg to 5 deg, taking the eye from the fixation point and then return it after a normal length intersaccadic interval of about 200ms (A) (36). Square wave pulses have a higher amplitude (usually greater than 5 deg) and a distinctive shorter intersaccadic interval (about 80 ms) than square wave jerks (B). Macrosaccadic oscillations occur in bursts of horizontal saccades that increase and then oscillate around a fixation point (C). Saccadic pulses are brief saccadic intrusions immediately followed by a slow glissadic drift to the previous position (D). Flutter and opsoclonus consist in saccadic oscillations without intersaccadic interval. Flutter occurs in the horizontal direction only (E), opsoclonus in multiple directions.

Figure 9. The head impulse test. The patient is asked to fixate the examiner's nose, while a 15° head rotation is actively and briskly given. In case of normal VOR, the gaze is held steady on the nose; in case of abnormal VOR, a corrective saccade will help to refixate the nose at the end of the rotation. This saccade indicates improper functioning of the VOR, and corresponds to the visual instability during head movements described by the patient.

REFERENCES

1. Tilikete C, Vighetto A. Oscillopsia: causes and management. *Current opinion in neurology*. 2011;24(1):38-43.
2. Abadi RV, Whittle JP, Worfolk R. Oscillopsia and tolerance to retinal image movement in congenital nystagmus. *Investigative ophthalmology & visual science*. 1999;40(2):339-45.
3. Abadi RV, Gowen E. Characteristics of saccadic intrusions. *Vision research*. 2004;44(23):2675-90.
4. Leigh RJ, Zee DS. The neurology of eye movements. Gilman S, Herdman WJ, editors. University of Michigan Medical Center: Oxford University Press; 2006.
5. Eizenman M, Cheng P, Sharpe JA, Frecker RC. End-point nystagmus and ocular drift: an experimental and theoretical study. *Vision research*. 1990;30(6):863-77.
6. Biousse V, Newman NJ. *Neuro-Ophthalmology illustrated*. New York: Thieme medical publisher; 2009.
7. Baloh RW, Yee RD, Honrubia V, Jacobson K. A comparison of the dynamics of horizontal and vertical smooth pursuit in normal human subjects. *Aviation, space, and environmental medicine*. 1988;59(2):121-4.
8. Liu GT, Volpe NJ, Galetta SL. *Neuro-Ophtalmology: diagnosis and management*. 2nd ed. Philadelphia: Saunders Elsevier; 2010.
9. Dupre M, Hermann R, Froment Tilikete C. Update on Cerebellar Ataxia with Neuropathy and Bilateral Vestibular Areflexia Syndrome (CANVAS). *Cerebellum*. 2020.
10. Gaymard B. Cortical and sub-cortical control of saccades and clinical application. *Revue neurologique*. 2012;168(10):734-40.
11. Wong AM. Understanding skew deviation and a new clinical test to differentiate it from trochlear nerve palsy. *Journal of AAPOS : the official publication of the American Association for Pediatric Ophthalmology and Strabismus / American Association for Pediatric Ophthalmology and Strabismus*. 2010;14(1):61-7.
12. Halmagyi GM, Curthoys IS, Brandt T, Dieterich M. Ocular tilt reaction: clinical sign of vestibular lesion. *Acta oto-laryngologica Supplementum*. 1991;481:47-50.
13. Jacob M, Vighetto A, Bernard M, Tilikete C. Ocular neuromyotonia secondary to a cavernous sinus meningioma. *Neurology*. 2006;66(10):1598-9.
14. Lenzi GL, Fieschi C. Superior orbital fissure syndrome. Review of 130 cases. *European neurology*. 1977;16(1-6):23-30.
15. Walsh FB. Myasthenia Gravis and Its Ocular Signs: A Review. *Transactions of the American Ophthalmological Society*. 1943;41:556-624.
16. Bosley TM, Schatz NJ. Clinical diagnosis of cavernous sinus syndromes. *Neurologic clinics*. 1983;1(4):929-53.
17. Desestret V, Streichenberger N, Panouilleres M, Pelisson D, Plus B, Duyckaerts C, et al. An elderly woman with difficulty reading and abnormal eye movements. *J Neuroophthalmol*. 2013;33(3):296-301.
18. Wong AMF. *Eye movement disorders*. Oxford, New York: Oxford University Press; 2008.
19. Ropper AH. Miller Fisher syndrome and other acute variants of Guillain-Barre syndrome. *Bailliere's clinical neurology*. 1994;3(1):95-106.
20. Tilikete C, Robert M. Ocular Motor Apraxia In: Shaikh A GF, editor. *Advances in Translational Neuroscience of Eye Movement Disorders Contemporary Clinical Neuroscience*. Springer ed2020.
21. Zee DS, Yee RD, Singer HS. Congenital ocular motor apraxia. *Brain : a journal of neurology*. 1977;100(3):581-99.
22. Bronstein AM. Oscillopsia: editorial review. *Current opinion in neurology*. 2005;18(1):1-3.
23. Zee DS. Ophthalmoscopy in examination of patients with vestibular disorders. *Annals of neurology*. 1978;3(4):373-4.

24. Huh YE, Kim JS. Patterns of spontaneous and head-shaking nystagmus in cerebellar infarction: imaging correlations. *Brain : a journal of neurology*. 2011;134(Pt 12):3662-71.
25. Choi KD, Oh SY, Park SH, Kim JH, Koo JW, Kim JS. Head-shaking nystagmus in lateral medullary infarction: patterns and possible mechanisms. *Neurology*. 2007;68(17):1337-44.
26. Minor LB, Haslwanter T, Straumann D, Zee DS. Hyperventilation-induced nystagmus in patients with vestibular schwannoma. *Neurology*. 1999;53(9):2158-68.
27. Baloh RW, Honrubia V, Konrad HR. Periodic alternating nystagmus. *Brain : a journal of neurology*. 1976;99(1):11-26.
28. Pullicino P, Lincoff N, Truax BT. Abnormal vergence with upper brainstem infarcts: pseudoabducens palsy. *Neurology*. 2000;55(3):352-8.
29. Pierrot-Deseilligny C, Milea D. Vertical nystagmus: clinical facts and hypotheses. *Brain : a journal of neurology*. 2005;128(Pt 6):1237-46.
30. Halmagyi GM, Aw ST, Dehaene I, Curthoys IS, Todd MJ. Jerk-waveform see-saw nystagmus due to unilateral meso-diencephalic lesion. *Brain : a journal of neurology*. 1994;117 (Pt 4):789-803.
31. Nakada T, Kwee IL. Seesaw nystagmus. Role of visuovestibular interaction in its pathogenesis. *Journal of clinical neuro-ophthalmology*. 1988;8(3):171-7.
32. Tilikete C, Jasse L, Pelisson D, Vukusic S, Durand-Dubief F, Urquizar C, et al. Acquired pendular nystagmus in multiple sclerosis and oculopalatal tremor. *Neurology*. 2011;76(19):1650-7.
33. Barton JJ, Cox TA, Digre KB. Acquired convergence-evoked pendular nystagmus in multiple sclerosis. *Journal of neuro-ophthalmology : the official journal of the North American Neuro-Ophthalmology Society*. 1999;19(1):34-8.
34. Guillain G, Mollaret P. Deux cas de myoclonies synchrones et rythmées vélopharyngo-oculo-diaphragmatiques. Le problème anatomique et physio-pathologique de ce syndrome. *Revue neurologique*. 1931(2):545-66.
35. Tilikete C, Desestret V. Hypertrophic Olivary Degeneration and Palatal or Oculopalatal Tremor. *Front Neurol*. 2017;8:302.
36. Lemos J, Eggenberger E. Saccadic intrusions: review and update. *Current opinion in neurology*. 2013;26(1):59-66.
37. Hotson JR. Convergence-initiated voluntary flutter: a normal intrinsic capability in man. *Brain research*. 1984;294(2):299-304.
38. Hoyt WF, Keane JR. Superior oblique myokymia. Report and discussion on five cases of benign intermittent uniocular microtremor. *Archives of ophthalmology*. 1970;84(4):461-7.
39. Black RA, Halmagyi GM, Thurtell MJ, Todd MJ, Curthoys IS. The active head-impulse test in unilateral peripheral vestibulopathy. *Archives of neurology*. 2005;62(2):290-3.
40. Newman-Toker DE, Kattah JC, Alvernia JE, Wang DZ. Normal head impulse test differentiates acute cerebellar strokes from vestibular neuritis. *Neurology*. 2008;70(24 Pt 2):2378-85.
41. Demer JL, Honrubia V, Baloh RW. Dynamic visual acuity: a test for oscillopsia and vestibulo-ocular reflex function. *The American journal of otology*. 1994;15(3):340-7.



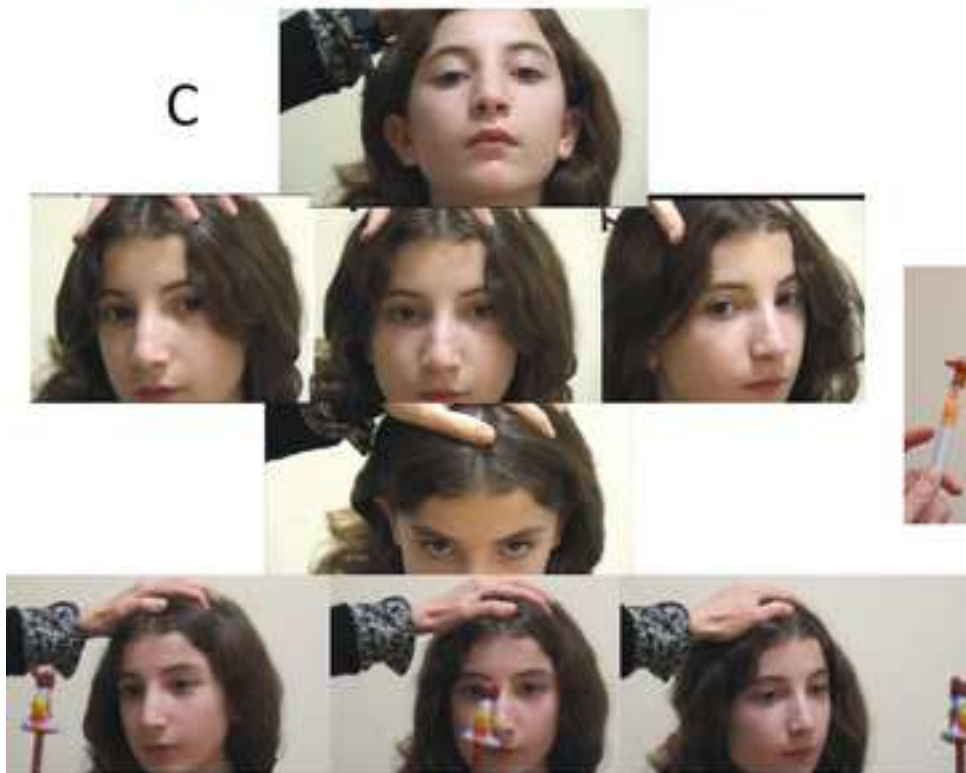A




B



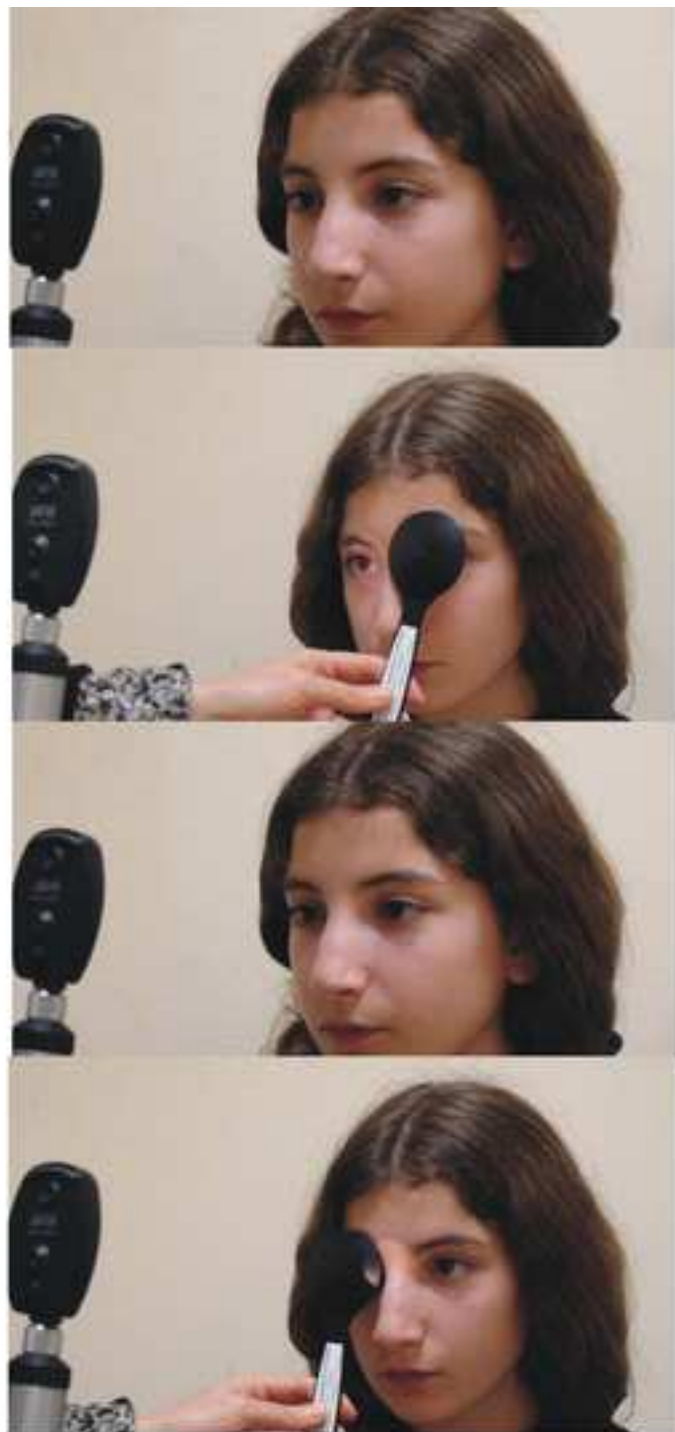C



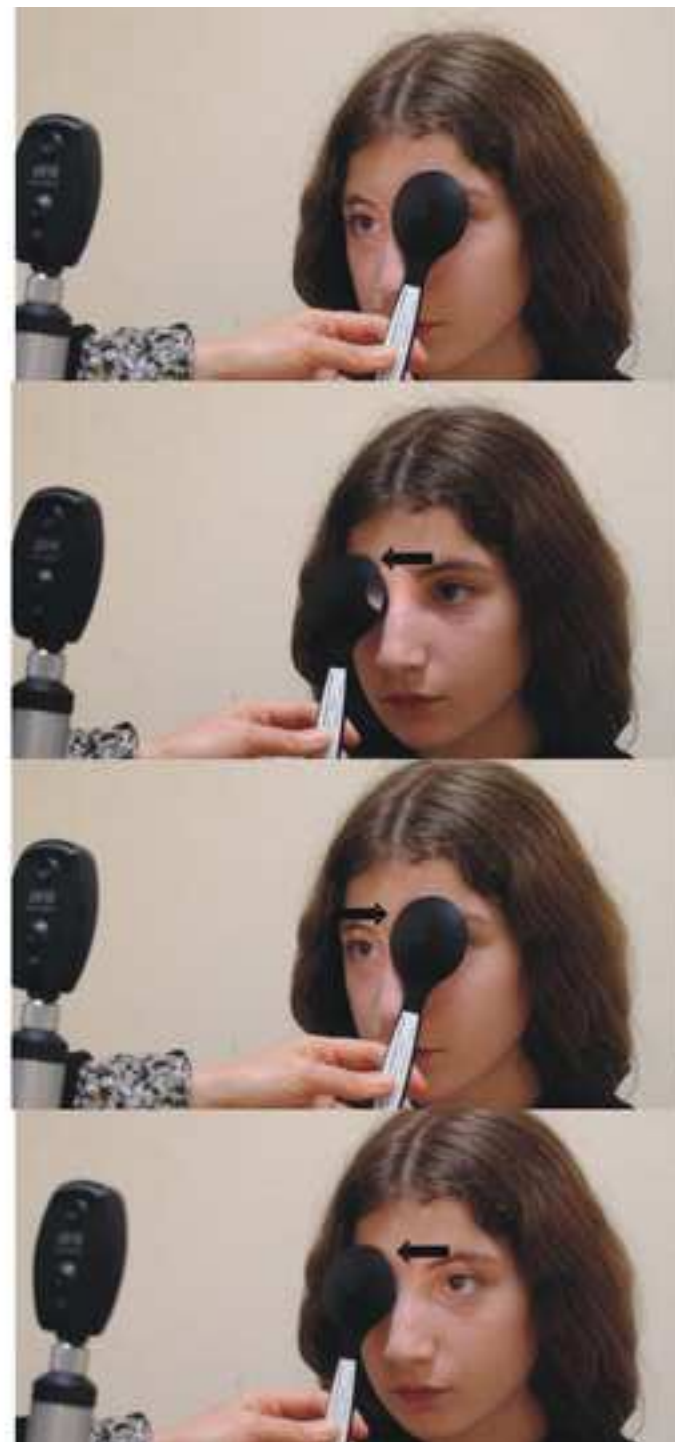D

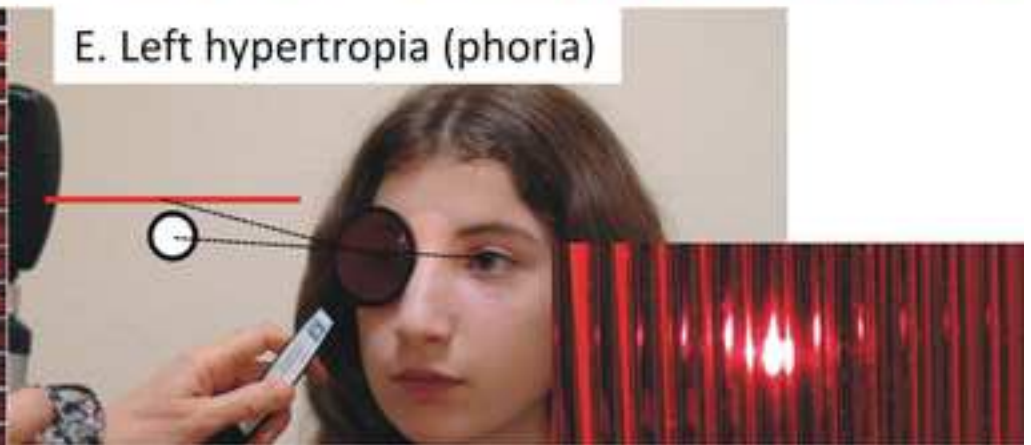
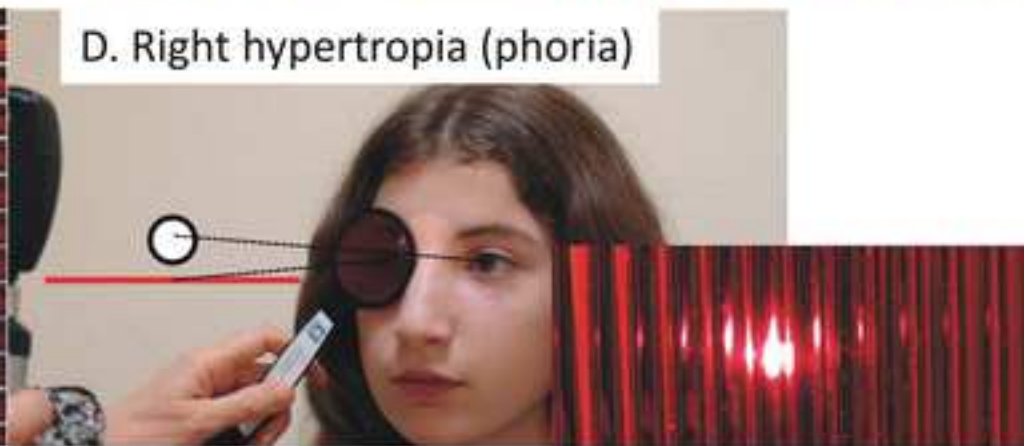



A

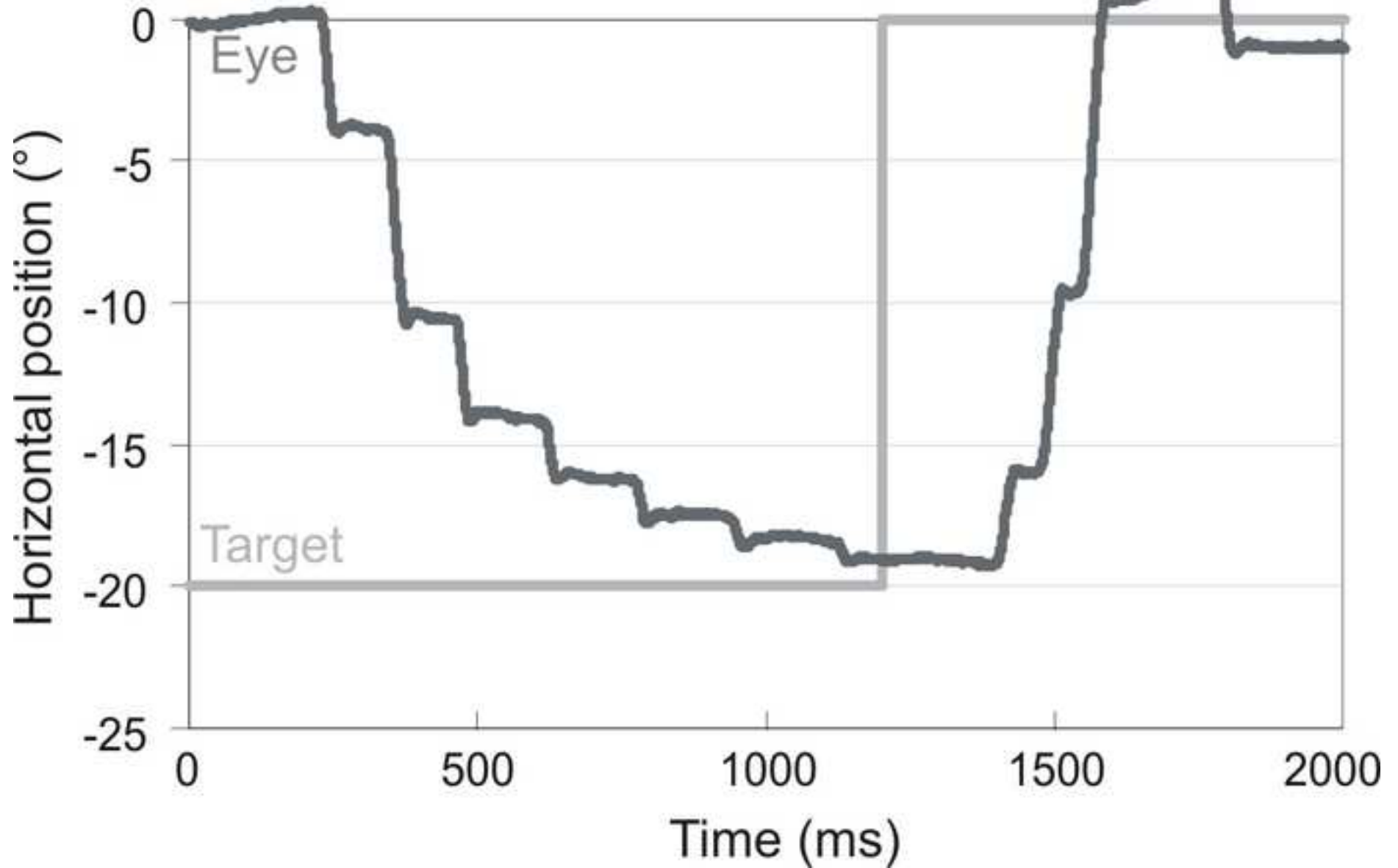


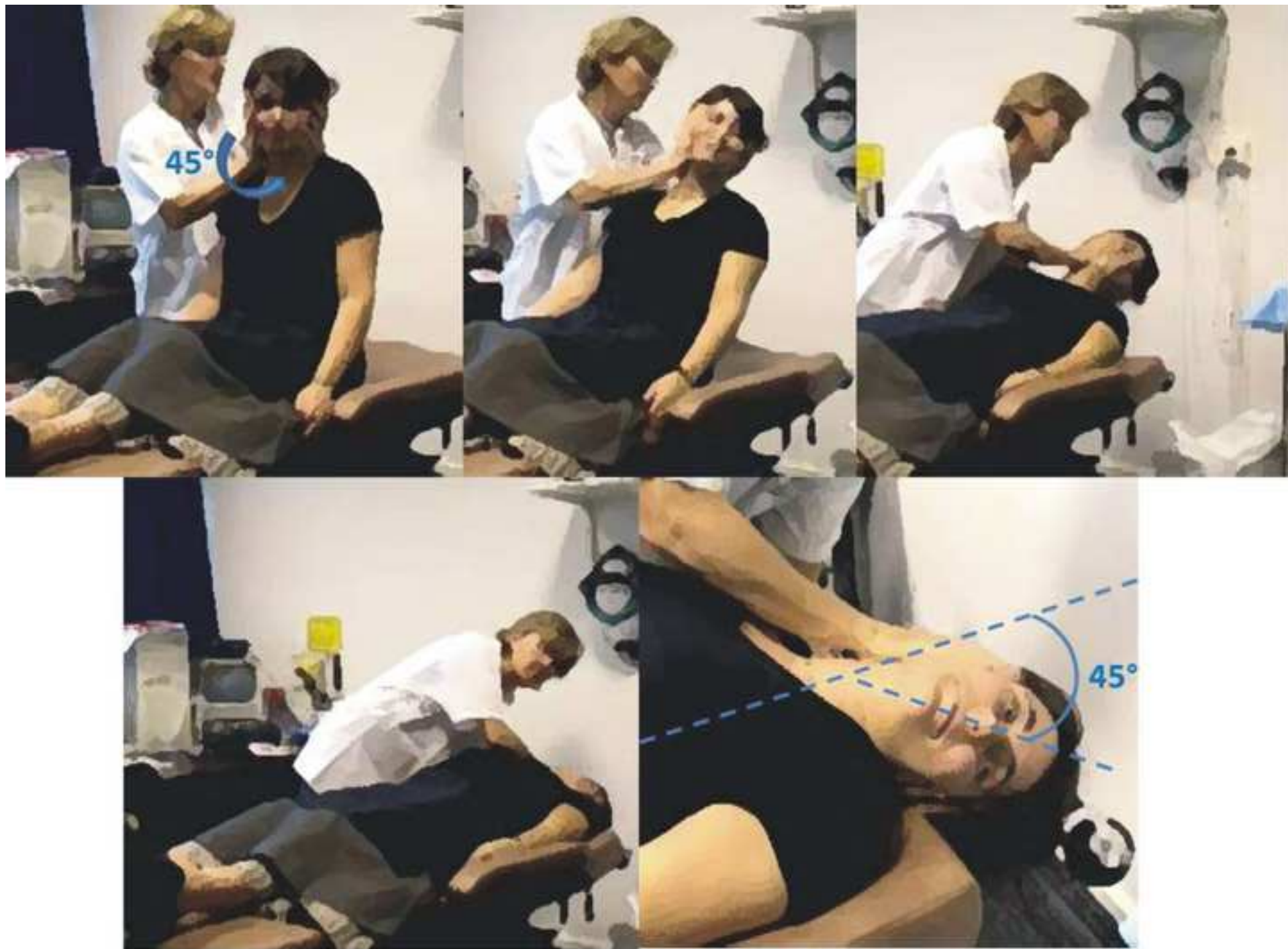B





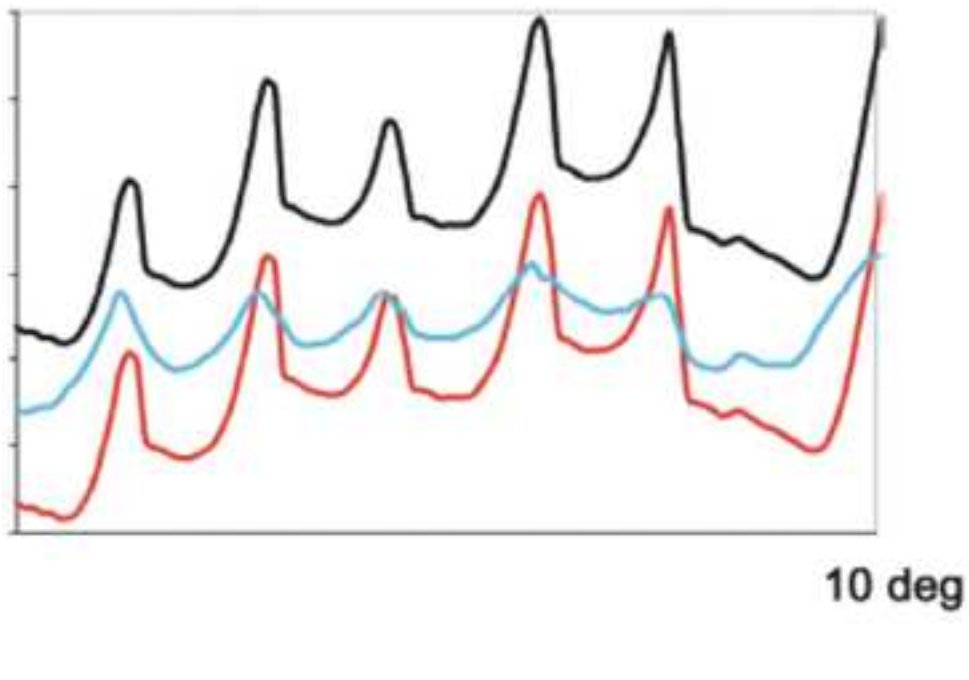
Staircase saccades



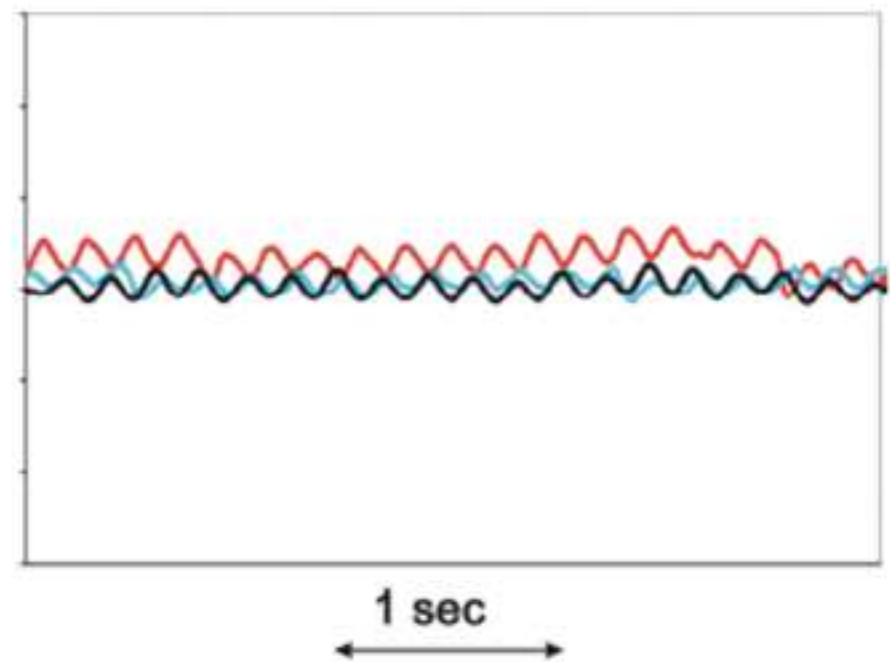


PENDULAR NYSTAGMUS

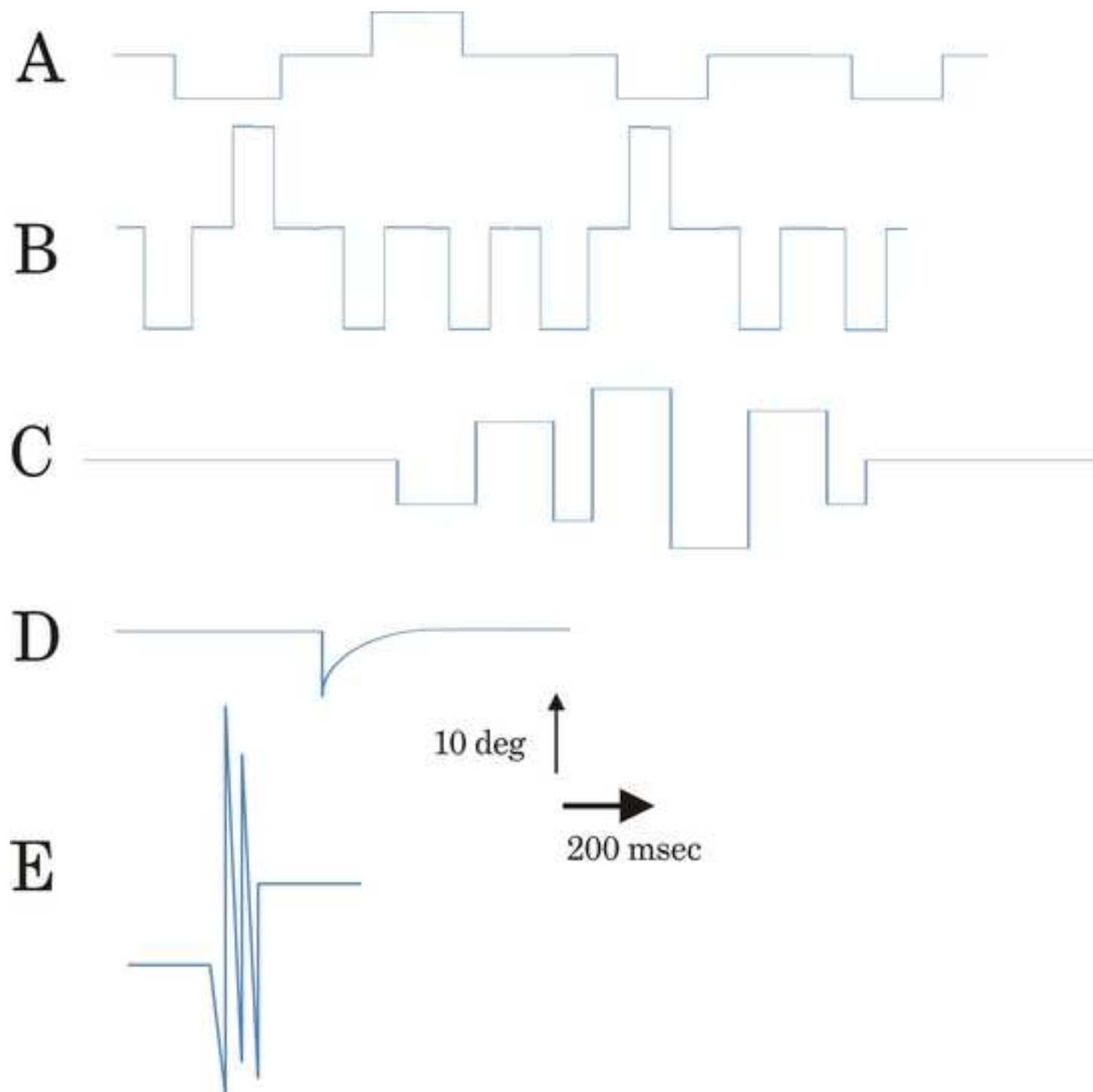
OCULOPALATAL TREMOR



MULTIPLE SCLEROSIS



HORIZONTAL VERTICAL TORSIONNAL



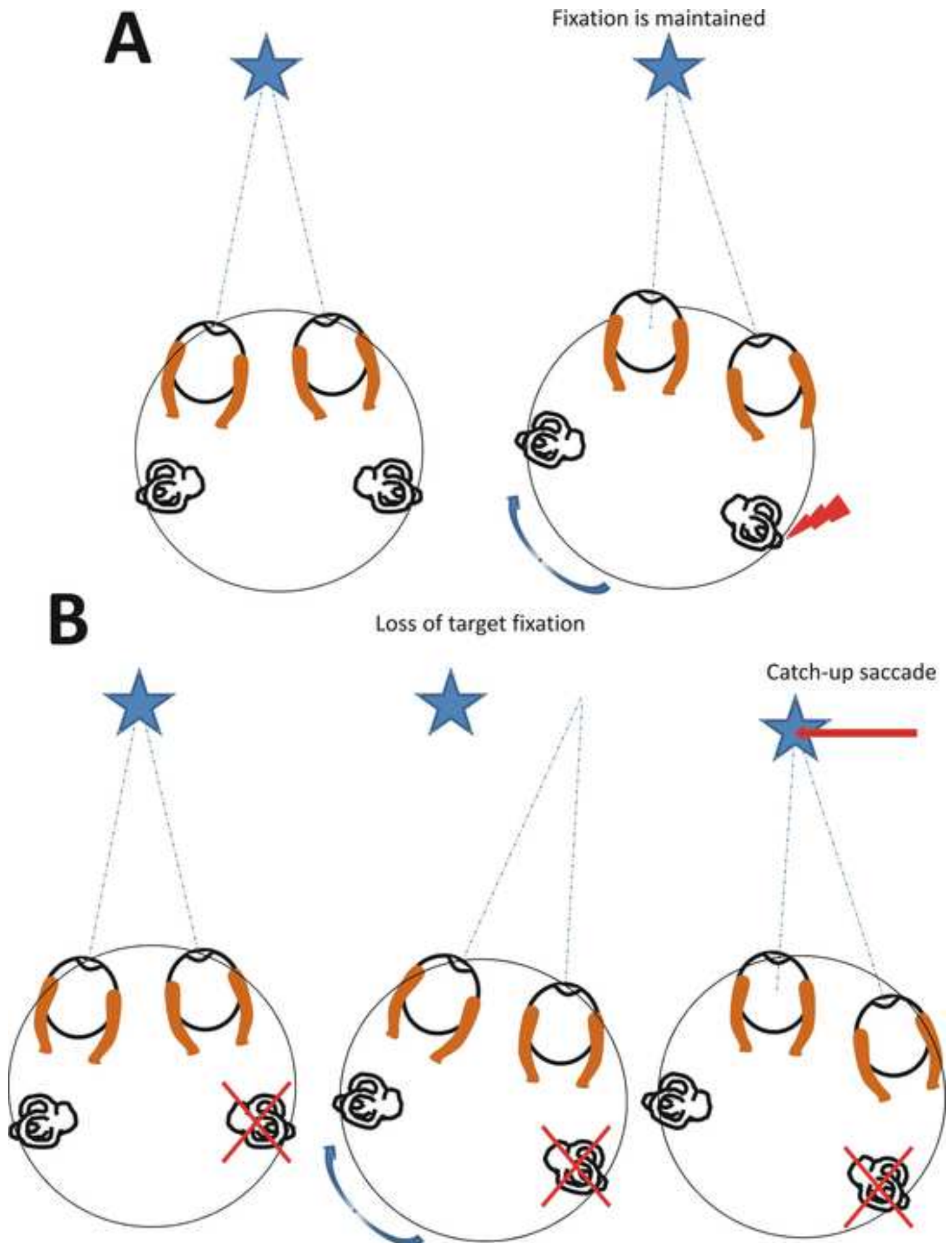


Table 1. Definition of the different types of abnormal eye movements

1. Ocular drifts: unregular small amplitude eye movement, mainly observed in blind patients.
2. Nystagmus : regular to-and-fro eye oscillations initiated by a slow eye movement (slow phase)
 - a. Jerk form : slow phase followed by a corrective saccade named quick phase
 - b. Pendular form: slow-phase oscillations without quick phases
3. Saccadic intrusions: fast eye movements that interrupt fixation, ranging from isolated saccades to sustained saccadic oscillations.

Table 2. The main steps of examining patient with binocular diplopia

1. Recognize limitation of eye movement using duction and version tests
2. In some case of important limitation, use the forced duction test
3. In case of no obvious limitation of eye movements, demonstrate ocular misalignment :
 - a. heterotropia by using the cover-uncover test
 - b. in case of orthotropia, heterophoria by using the cross cover test
4. In case of small ocular misalignment, characterize the disparity between retinal images by using the red glass and/or the Maddox rod test
5. In case of vertical misalignment
 - a. Use the 4 steps test
 - b. Use the lying test

Table 3. The four steps test for vertical diplopia

1. Step 1 determines the side of hypertropia in primary position.
2. Step 2 determines whether hypertropia increases in right or left gaze.
3. Step 3 determines whether hypertropia increases in up or down gaze.
4. Step 4 determines whether the hypertropia increases on right or left head tilt.

Table 4. Triggering maneuvers for vestibular nystagmus

1. During suppression of visual fixation (using Frenzel goggles or ophthalmoscopy)
2. Following head-shaking test, by asking the patient to vigorously shake the head for 10 to 15 sec side to side, then up and down
3. Following a sustained (30 sec) hyperventilation
4. During Valsalva maneuver.
5. In the Dix-Hallpike maneuver